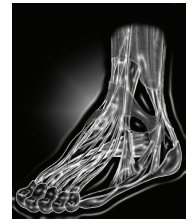




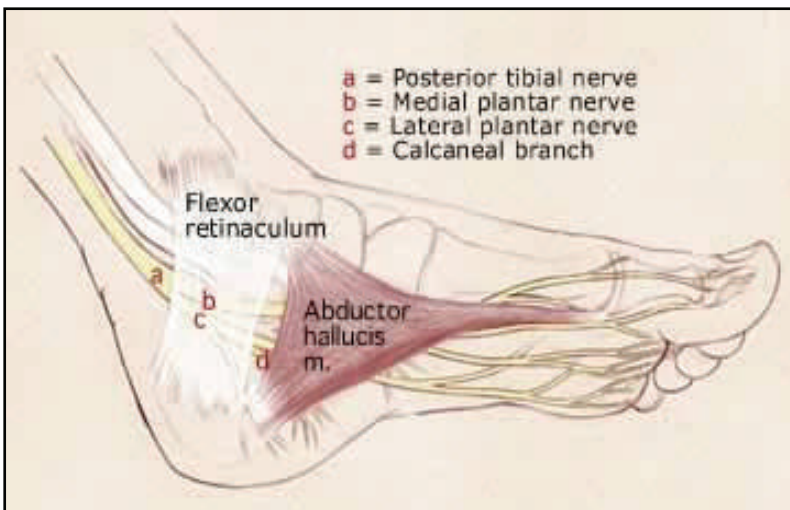
*Adam D. Perler, DPM, FACFAS*  
Foot & Ankle Reconstructive Surgery



## Tarsal Tunnel Syndrome

### Anatomy of the Tarsal Tunnel

The tarsal tunnel is the region beneath the flexor retinaculum on the medial side of the ankle. The contents of the tarsal tunnel are the posterior tibial nerve and the posterior tibialis artery and two accompanying veins. The posterior tibial nerve most commonly divides into the medial and lateral plantar nerves within this tunnel.



Tarsal Tunnel Syndrome is traditionally known as a single region of compression on the posterior tibial nerve by the flexor retinaculum. However, there are actually **three other sites of compression**, in addition to the tarsal tunnel, that need to be decompressed in order to correct the patient's problems.

The other sites are:

The **calcaneal tunnel** (for the medial calcaneal n., **d**)

The **medial plantar tunnel** (for the medial plantar n., **b**)

The **lateral plantar tunnel** (for the lateral plantar n., **c**)

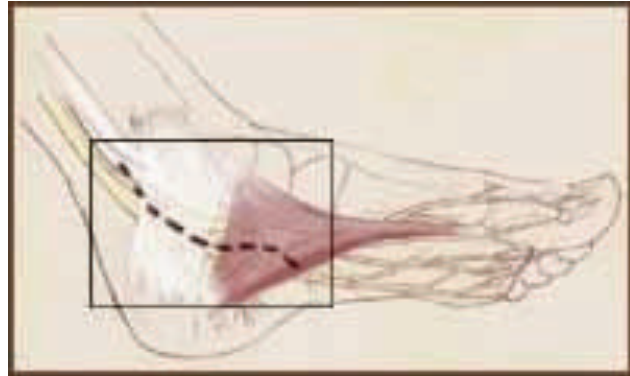
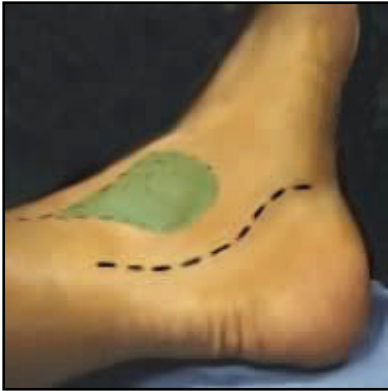Variations predisposing a person to nerve compression at the ankle:

The posterior tibial nerve most commonly divides into the medial and lateral plantar nerves within this tunnel. In about 5% of people, this division will occur proximal to the entrance of the tunnel, so that at the time these nerves enter the tunnel they already occupy about twice the volume of the posterior tibial nerve.

### Surgery of the Tarsal Tunnel

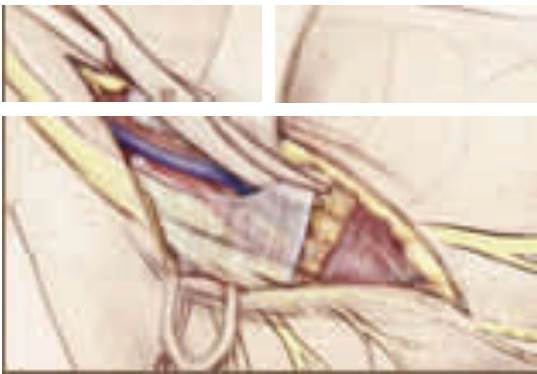
Surgery for the tarsal tunnel should only be considered if all non-operative treatment options have not been successful at relieving pain and other symptoms. The surgery is conducted to relieve the pressure on the posterior tibial nerve and its branches.

The operation requires an incision that is made from just below the ankle bone (medial malleolus -- shown in green), and that continues in a gentle s-shaped curve to the beginning of the arch of your foot. (**Below - left**: incision shown by black dashed line). The incision spans the flexor retinaculum and the abductor hallucis muscle (area in rectangle **below - right**).



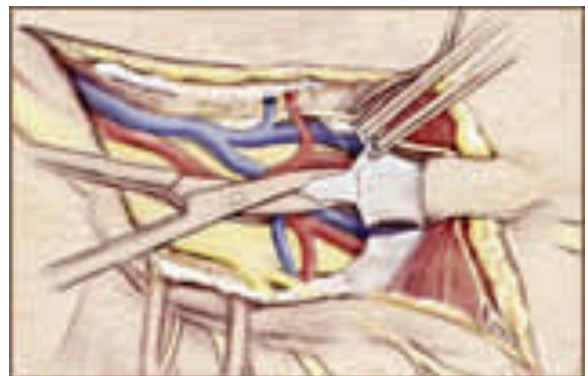
### Procedure

1. The flexor retinaculum is being divided to expose the underlying structures. The abductor hallucis muscle is covering the medial and lateral plantar tunnels.

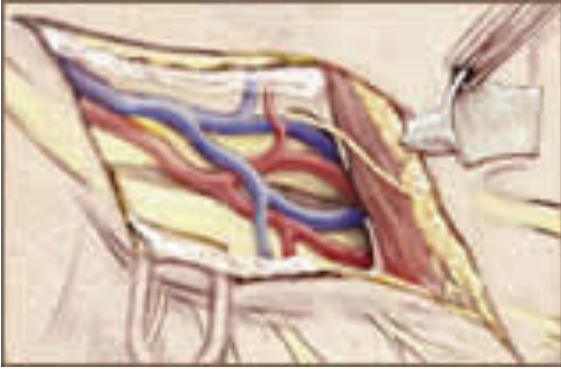

2. The abductor hallucis muscle is pulled back, its fascia forming the medial and lateral tunnels is divided above each tunnel; and finally the septum is divided.

3. Once the septum is removed the vessels and nerves share a common tunnel, allowing more room for movement and less compression.



### *Surgical Treatment*



**3.** Once the septum is removed the vessels and nerves share a common tunnel, allowing more room for movement and less compression.

### *Post-operative Care*

In the post-operative period the patient is encouraged to use the foot as little as possible. The foot is wrapped in what is called a bulky Robert Jones dressing (see below).

The Robert Jones dressing is a large amount of cotton that is wrapped around the ankle and the foot. The purpose of such a bulky dressing is to partially immobilize the leg and minimize the swelling, and yet protect the foot in case there is a need to put weight on it. Most people will use crutches for the first three weeks; for heavier or older patients, a walker may be utilized.



The dressing is removed one week following surgery, and it is generally successful in having little swelling and little bruising. Sutures are left on for three weeks since it takes 3 weeks for skin to regain 90 % of its original strength. We want the nerves to glide post-operatively, so it is critical during the 2nd and 3rd weeks following the surgery that the posterior tibial nerve and its branches be able to move in the tunnels. An air cast is applied so that the ankle has some range of motion, and allows movement of the toes so that the nerves do not become adherent to the surrounding tissue.